

Protective Effects of *Ocimum gratissimum* Polyphenol Extract on Carbon Tetrachloride-Induced Liver Fibrosis in Rats

Yieng-How Chen¹, Yung-Wei Chiu^{2, 3}, Jyh-Cherng Shyu⁴, Chin-Chiu Tsai⁴,
Hsueh-Hui Lee⁵, Chuan-Chen Hung⁶, Jin-Ming Hwang⁷, Jer-Yuh Liu^{8, 9},
and Wen-Hong Wang¹⁰

¹Department of Animal Science and Biotechnology, Tunghai University, Taichung 40704

²Institute of Medicine, College of Medicine, Chung Shan Medical University, Taichung 40201

³Emergency Department, Tungs' Taichung MetroHarbor Hospital, Taichung 43549

⁴Department of Physiology, School of Medicine, College of Medical, Chung Shan Medical University
Taichung 40201

⁵Department of Laboratory Medicine, Kuang Tien General Hospital, Taichung 43303

⁶Institute of Biochemistry and Biotechnology, College of Medical, Chung Shan Medical University
Taichung 40201

⁷School of Applied Chemistry, Chung Shan Medical University, Taichung 40201

⁸Center for Molecular Medicine, China Medical University Hospital, Taichung 40447

⁹Graduate Institute of Cancer Biology, China Medical University, Taichung 40402
and

¹⁰Department of food and nutrition, Taichung Veterans General Hospital, Taichung 40705
Taiwan, Republic of China

Abstract

Ocimum gratissimum found in tropical regions is a traditional herb commonly which prevents free radical damage and protects liver from oxidative stress and fibrosis. *Ocimum gratissimum* polyphenol extract (OGPE) was purified by resin tube to 33.24% polyphenol and 8.2% flavonoid, which were three-fold higher compared with the pre-purification concentrations. The abstract was used to determine if the antioxidant components in the *O. gratissimum* extract (OGE) were responsible for protective effects on liver fibrosis. High-performance liquid chromatography analysis revealed that the content levels of catechin, caffeic acid and epicatechin in OGPE also increased three-fold. Male Wistar rats were administered with carbon tetrachloride (CCl₄) and varying amounts of OGPE doses [0-12 mg/kg body weight (BW)] or OGE dose (40 mg/kg BW) for 8 weeks. Results showed that OGPE at 12 mg/kg BW, similar to OGE at 40 mg/kg BW, maintained the liver weight, significantly ameliorated CCl₄-induced steatosis, and mitigated other pathological changes. OGPE (12 mg/kg BW) also maintained the levels of serum alanine aminotransferase and aspartate aminotransferase, as well as the levels of malondialdehyde, catalase and α -smooth muscle actin in liver tissues from CCl₄-induced changes. These findings suggest that antioxidant components in OGPE were the major factors that prevented liver fibrosis. Moreover, higher polyphenol concentrations were necessary for higher effectiveness.

Key Words: liver fibrosis, *Ocimum gratissimum* polyphenol extract

Corresponding authors: [1] Wen-Hong Wang, Ms. D., Department of food and nutrition, Taichung Veterans General Hospital, Taichung, Taiwan Boulevard Sec. 4, Taichung 40705, Taiwan, R.O.C. Tel: +886-4-23592525 ext. 2626, Fax: +886-4-23595046, E-mail: whwang@vghtc.gov.tw; [2] Jin-Ming Hwang, Ph.D., School of Applied Chemistry, Chung Shan Medical University, No. 110, Sec. 1, Jianguo N. Rd., Taichung 40201, Taiwan, R.O.C. Tel: +886-4-24730022 ext. 12233, Fax: +886-4-23248189, E-mail: hjm@csmu.edu.tw; and [3] Jer-Yuh Liu, Ph.D., Graduate Institute of Cancer Biology, College of Medical, China Medical University, No. 91, Hsueh-Shih Rd., Taichung 40402, Taiwan, R.O.C. Tel: +886-4-22052121 ext. 7932, Fax: +886-4-22347028, E-mail: jyl@mail.cmu.edu.tw

Received: March 27, 2014; Revised: May 27, 2014; Accepted: June 11, 2014.

©2015 by The Chinese Physiological Society and Airiti Press Inc. ISSN : 0304-4920. <http://www.cps.org.tw>

Introduction

Oxidative stress is an important factor that induces liver fibrosis and a key feature of hepatitis induced by conditions such as anoxic/reoxygenation injury, autoimmune hepatitis, viral hepatitis and alcoholic hepatitis (30). Exposure to minimum amounts of oxidative stress over a long period may induce activation of and morphological changes in hepatic stellate cells (HSCs). These changes, including increase in proliferative activity, synthesis, and degradation/remodeling of the extracellular matrix, chemotaxis, contractility, pro-inflammatory activity and retinoid loss (16), can cause liver fibrosis progression.

Carbon tetrachloride (CCl₄) is a xenobiotic used extensively as an industrial solvent, and is employed in research to induce oxidative stress. CCl₄ is assumed to initiate free radical-mediated lipid peroxidation that leads to the accumulation of lipid-derived oxidation products (31, 32, 36) and excess collagen deposition in the liver, resulting in liver fibrosis. Researchers have previously demonstrated that natural antioxidants, particularly polyphenols and flavonoids, prevent CCl₄ toxicity, especially hepatotoxicity, by inhibiting lipid peroxidation (34), suppressing alanine aminotransferase (ALT) and aspartate aminotransferase (AST) activities (34), and increasing antioxidant enzyme activities (17).

Ocimum gratissimum is commonly used in folk medicine and is widely distributed in tropical and warm temperate geo-locations (15, 28). *O. gratissimum* consists of abundant antioxidants and possesses many therapeutic functions, including anti-inflammation (21), analgesic and spasmolytic activities (5), antidiarrheal (15), antitumor (27), antiviral (4) and antihyperglycemic activities (2), and improves phagocytic function without affecting the humoral or cell-mediated immune system (3). Moreover, *O. gratissimum* extract (OGE) has protective effects in cardiac (8) and liver (9, 13, 22) tissues, and inhibits lipid peroxidation, thereby preventing free radical damage and protecting organs from oxidative stress.

Recent reports have demonstrated that OGE can inhibit HSC activation and has protective effects against liver fibrosis (10). However, it remains unclear whether or not polyphenol and flavonoids in OGE are responsible for the protective effects. To elucidate this protective effect, this study investigated the effectiveness of *Ocimum gratissimum* polyphenol extract (OGPE) against OGE to prevent CCl₄-induced liver fibrosis.

Materials and Methods

Preparation of OGPE

O. gratissimum leaves were washed, and then boiled with distilled water for 1 h. The solution was

chilled to 4°C and filtered through two layers of gauze. The filtrate was centrifuged at 20,000 × *g* at 4°C for 15 min to remove insoluble pellets. The supernatant (OGE) was then collected, lyophilized and stored at -20°C. For purification, 10 g of OGE was dissolved with 500 ml distilled water. Polyphenols and flavonoids were obtained with a resin tube during *O. gratissimum* polyphenol extract (OGPE) solution filtration to purify OGE (23). The resin tube was then rinsed with alcohol to separate the extract. Finally, the extract was lyophilized and stored at -20°C.

Polyphenol Content Measurement

The method used by Singleton *et al.* (33) was carried out. Distilled H₂O (10 ml), Folin-Ciocalteu reagent (0.5 ml) and the extract (1 ml) were mixed, shaken, and kept at room temperature for 15 min. Approximately 3 ml 20% Na₂CO₃ was added to the solution, and the mixture was heated at 100°C for 1 min in a water bath. The polyphenol content was calibrated to gallic acid standard using a spectrophotometer at 725 nm.

Flavonoid Content Measurement

The AlCl₃ method (20) was used to determine the flavonoid content. Methanolic extract solution (1 ml) was added to 1 ml 2% methanolic AlCl₃ (6H₂O) and the mixture was allowed to react for 6 min. Up to 4 ml 4% NaOH was added to the solution, and the mixture was left to stand for 15 min. Absorbance was measured at 510 nm using rutin as a standard.

High-Performance Liquid Chromatography (HPLC) Analysis

Extracted methanolic solutions (20 µl), filtered on Millipore membrane (0.45 µm), were analyzed on a Lichrospher 100 RP 18 (5 µm) C18 column (4.6 × 1506 mm) with an acidic CH₃CN:H₂O gradient. The linear gradient detected by an elution program using an L-4250 UV-vis detector set at 280 nm at a 1 ml/min flow rate was as follows: 0 to 10 min, 5% to 10% B in A; 10 to 20 min, 10% to 20% B in A; 20 to 30 min, 20% to 30% B in A; 30 to 40 min, 30% to 40% B in A; 40 to 55 min, 40% to 55% B in A; 55 to 60 min, 45% to 20% A in B; 60 to 65 min, 20% to 0% A in B; 65 to 70 min, 0% to 50% A in B; 70 to 75 min, 50% to 30% B in A; and 75 to 80 min, 30% to 10% B in A [A: acetic acid/water (2%, v/v); B: 0.5% acetic acid in water/acetonitrile (50:50, v/v), both adjusted to pH 2.6 with *O*-phosphoric acid] at -30°C. Gallic acid, protocatechuic acid, catechin, epigallocatechin gallate, caffeic acid, epicatechin, rutin, quercetin and naringenin were quantified by comparison with pure standards.

Animals and Treatment

Male Wistar rats weighing 200-240 g were housed in conventional cages with free access to water and rodent chow at 20-22°C with a 12-hour light-dark cycle. All procedures that involved laboratory animal use were in accordance with the guidelines of the Institutional Animal Care and Use Committee of China Medical University for the care and use of laboratory animals. Rats were treated intraperitoneally with CCl₄ [8% CCl₄/corn oil; 1 ml/kg body weight (BW) twice a week; Monday and Thursday] for 8 weeks, as described by Hernandez-Munoz *et al.* (14), with some modifications. The rats were orally treated with various dosages of OGE (40 mg/kg BW) or OGPE (0-12 mg/kg BW) four times a week (Tuesday, Wednesday, Friday, and Saturday) (24, 25). Control rats were treated with corn oil and fed a normal diet. At the end of the experiment, blood and livers were immediately obtained after the animals were sacrificed. Liver tissue samples were obtained from the left liver lobe and cut into two pieces. One piece was fixed in formalin for pathological examination; the other piece was used for further biological analyses. Liver homogenates (10%, w/v) were obtained in 50 mM phosphate buffer, pH 7.0, and stored at -80°C for analysis within 2 weeks.

Histological Examinations

A portion of the liver was fixed in 10% formalin, processed using routine histology procedures, embedded in paraffin, cut into 5- μ m sections, and mounted on a slide. The samples were stained with hematoxylin and eosin for histopathological examination. Masson stain was used to confirm CCl₄-induced liver fibrosis evidenced by fiber extensions and collagen accumulation. Liver steatosis was graded on a 3-point scale: 1+, hepatocytes in one-third of the lobules showing fatty accumulation; 2+, hepatocytes in two-thirds of the lobules; and 3+, hepatocytes in all lobules. The criteria used for scoring fibrosis severity were as follows: 0, normal; 1+, fibrosis present (collagen fiber present that extends from portal triad or central vein to peripheral region); 2+, mild fibrosis (collagen fiber present with extension without compartment formation); 3+, moderate fibrosis (collagen fiber present with some pseudo lobe formation); and 4+, severe fibrosis (collagen fiber present with thickening of the partial compartments and frequent pseudo lobe formation).

Measurement of Plasma Transaminase Activities

AST and ALT activities in the plasma were measured using Boehringer Mannheim reagents as

recommended by the International Federation of Clinical Chemistry Scientific Committee (6, 7).

Measurement of Hepatic Lipid Peroxidation

Lipid peroxidation was determined based on the amount of thiobarbituric acid-reactive substances (TBARS) (11). The fluorescence of the samples was detected at an excitation wavelength of 515 nm and an emission wavelength of 555 nm in a F4500 fluorescence spectrophotometer (Hitachi, Japan) using 1,1,3,3-tetramethoxypropane as the thiobarbituric acid-reactive standard.

Preparation of Tissue Extract

All procedures were performed at 4°C. Liver samples were lysed by 30 strokes using a Konetes homogenizer at a ratio of 100 mg tissue/ml lysis buffer. The lysis buffer consisted of 50 mM Tris-HCl, pH 7.4, 2 mM EDTA, 2 mM EGTA, 150 mM NaCl, 1 mM PMSF, 10 μ g/ml leupeptin, 1 mM sodium orthovanadate, 1% (v/v) 2-mercaptoethanol, 1% (v/v) Nonidet P40, and 0.3% sodium deoxycholate. The homogenates were centrifuged at 100,000 \times g for 1 h at 4°C. The supernatant was stored at -70°C for Western blot assay.

Electrophoresis and Western Blot

Tissue extract samples were prepared as described above. Sodium dodecyl sulfate-polyacrylamide gel electrophoresis was carried out as described by Laemmli (19) using 10% polyacrylamide gels. The samples were electrophoresed at 140 V for 3.5 h, and the gels were equilibrated for 15 min in 25 mM Tris-HCl, pH 8.3, containing 192 mM glycine and 20% (v/v) methanol. Electrophoresed proteins were transferred to nitrocellulose membrane (Hybond-C Extra Supported, 0.45 Micro) (Amersham) using a Hoefer Scientific Instruments Transphor Units at 100 mA for 14 h. The nitrocellulose membrane was incubated at room temperature for 2 h in blocking buffer containing 100 mM Tris-HCl, pH 7.5, 0.9% (w/v) NaCl, 0.1% (v/v) Tween 20 and 3% (v/v) fetal bovine serum. Antibodies against α -smooth muscle actin (α -SMA) (Sigma) and α -tubulin (Santa Cruz Biotechnology, Inc., USA) were diluted to 1:2,000 in an antibody binding buffer containing 100 mM Tris-HCl, pH 7.5, 0.9% (w/v) NaCl, 0.1% (v/v) Tween 20 and 1% (v/v) fetal bovine serum. Incubations were performed at room temperature for 3.5 h. The immunoblots were washed three times in 50 ml blotting buffer for 10 min and then immersed for 1 h in a second antibody solution containing horseradish peroxidase goat anti-rabbit IgG (Promega) for α -SMA, and horseradish peroxi-

Table 1. Phenol acid and flavonoid in OGE and OGPE

No.	Compound	Phenolic Compound (mg/g Extract)	
		Water Extract	Purified Extract
1	Gallic Acid	UD	UD
2	Protocatechuic Acid	UD	UD
3	Catechin	0.3	2.3
4	Epigallocatechin Gallate	UD	UD
5	Caffeic Acid	2.7	7.2
6	Epicatechin	3.7	11.7
7	Rutin	32.7	40.2
8	Quercetin	UD	UD
9	Naringenin	UD	UD

UD, compound level undetected

dase goat anti-mouse IgG (Promega) for α -tubulin, which were diluted in binding buffer to 1,000-fold. After washing with blocking buffer, the membrane was visualized using chemiluminescence (Amersham Pharmacia Biotech, Piscataway, NJ, USA).

Statistical Analysis

Experimental results were expressed as mean \pm SD. Data were assessed using ANOVA. Student's *t*-test was used to compare data between groups. *P* < 0.05 was considered statistically different.

Results

Polyphenol and Flavonoid Contents in OGPE

After the OGE was purified, the polyphenol and flavonoid concentrations of OGPE were 33.24% and 8.2%, respectively, which were three-fold higher compared with the pre-purification concentrations.

HPLC Analysis of OGPE Content

Following a spectrophotometer test from a previous experiment in which various flavonoids and polyphenols were found, an HPLC test was performed to analyze the content level of polyphenols and flavonoids of OGE and OGPE (Fig. 1). Comparison of the content levels of various polyphenols and flavonoids showed that catechin, caffeic acid and epicatechin were significantly raised at least three-fold from 0.3, 2.7, and 3.7 mg/g in OGE to 2.3, 7.2, and 11.7 mg/g in OGPE, respectively (Table 1). The rutin content was marginally increased from 32.7 to 40.2 mg/g.

BW of Rats during the Experiment

During the 8-week experiment, no significant

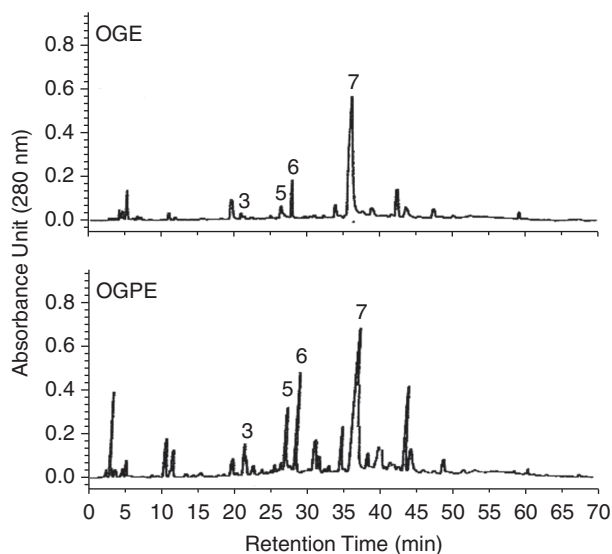


Fig. 1. HPLC analysis of polyphenol and flavonoid content in OGE and OGPE. Peak number 3 corresponds to the catechin; peak number 5 corresponds to the caffeic acid; peak number 6 corresponds to the epicatechin; peak number 7 corresponds to the rutin.

differences were observed in the bodyweight among all the test groups. The weight of all rats increased from about 120 g to about 350 g.

Organ Weight

The liver, kidney and spleen of the sacrificed rats were weighed. The organ weights of the groups relative to their bodyweights after 8 weeks were analyzed (Table 2). Liver weight was significantly increased in the CCl_4 -treated group (group B) compared with the control group A, whereas the groups co-treated with OGE or OGPE maintained their organ weight. Most changes in organ weights occurred in the liver;

Table 2. OGPE effects on the ratio of organ to body weight of CCl₄-induced liver fibrosis in rats after 8 weeks

Group ^a	Ratio of Liver and Body	Ratio of Spleen and Body	Ratio of Kidney and Body
A	3.35 ± 0.13 ^b	0.29 ± 0.06	0.73 ± 0.05
B	4.70 ± 0.66 [#]	0.33 ± 0.07	0.78 ± 0.04
C	3.58 ± 0.17*	0.29 ± 0.01	0.70 ± 0.03
D	4.48 ± 0.26 [#]	0.38 ± 0.07	0.80 ± 0.06
E	3.91 ± 0.65*	0.29 ± 0.02	0.74 ± 0.06

[#] $P < 0.05$ as compared with control group, * $P < 0.05$, as compared with CCl₄-treated group.

^aA, control sample; B, CCl₄-treated sample; C, CCl₄-treated sample with 40 mg OGE/kg BW; D, CCl₄-treated sample with 6 mg OGPE/kg BW; E, CCl₄-treated sample with 12 mg OGPE/kg BW. ^bThe data are expressed as mean ± SD, n = 8.

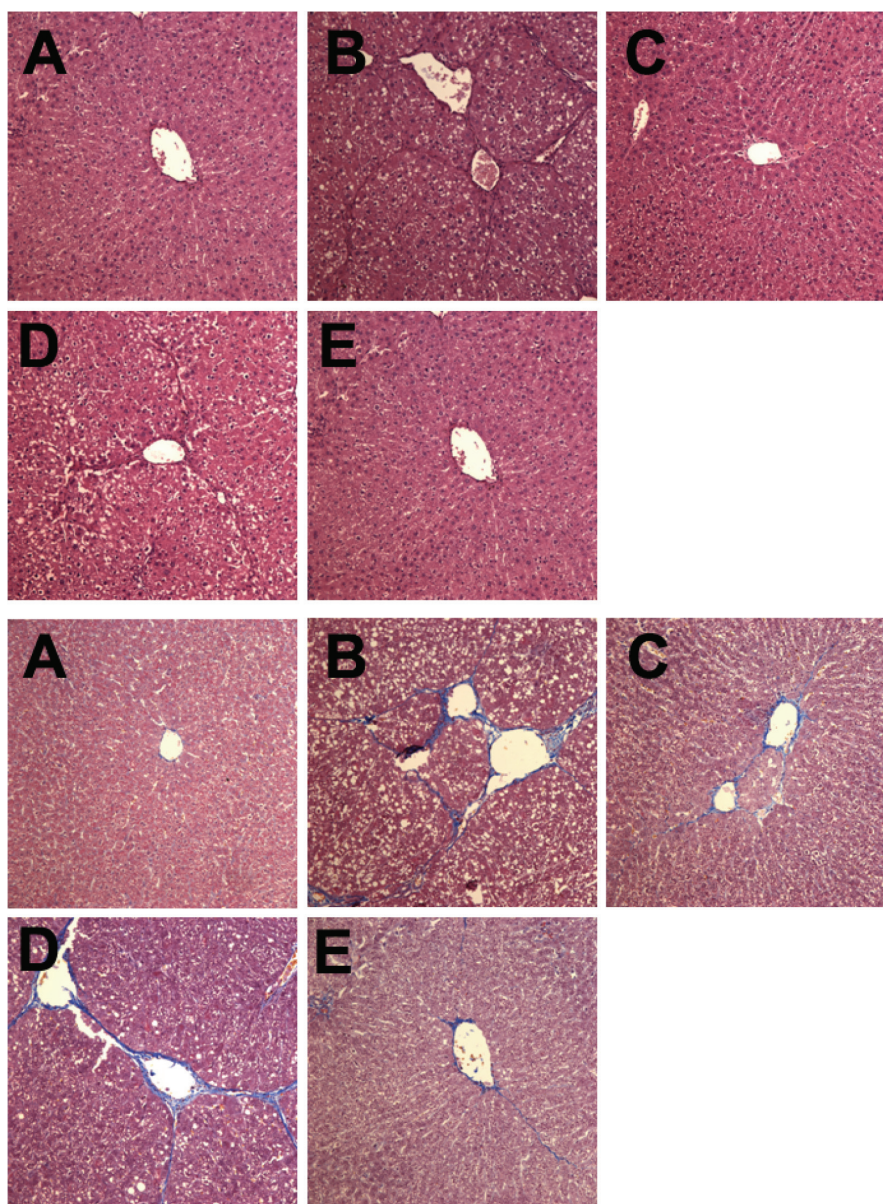


Fig. 2. Analysis of OGPE on liver pathology by H&E stain (upper panel) and Masson stain (down panel) after CCl₄ treatment in rats after 8 weeks. (A) Control sample; (B) CCl₄-treated sample; (C) CCl₄-treated sample with 40 mg OGE/kg BW; (D) CCl₄-treated sample with 6 mg OGPE/kg BW; (E) CCl₄-treated sample with 12 mg OGPE/kg BW. Magnification, ×400. Black arrows mark the locations of steatosis; blue areas indicate collagen fibers.

Table 3. OGPE effects on histopathological evidence of CCl₄-induced liver fibrosis in rats after 8 weeks

Group ^a	Severity Score of Fatty Metamorphosis						Severity Score of Hepatic Fibrosis					
	N	0	1	2	3	Average	0	1	2	3	4	Average
A	8	8	0	0	0	0.0 ± 0.0 ^b	8	0	0	0	0	0.0 ± 0.0
B	8	0	4	4	0	1.5 ± 0.5 ^{##}	0	0	6	2	0	2.3 ± 0.5 ^{##}
C	8	2	6	0	0	0.8 ± 0.5*	0	6	2	0	0	1.3 ± 0.5*
D	8	0	6	2	0	1.3 ± 0.5 ^{##}	0	0	8	0	0	2.0 ± 0.0 ^{##}
E	8	2	6	0	0	0.8 ± 0.5*	0	7	1	0	0	1.1 ± 0.4*

^{##}*P* < 0.01 as compared with control group. **P* < 0.05 as compared with CCl₄-treated group. ^{a, b}Grouping and data presentation are as in the footnote to Table 2.

Table 4. OGPE effects on serum ALT, AST, ALP, LDH and cholesterol after CCl₄ treatment in rats after 8 weeks

Group ^a	ALT (IU/L)	AST (IU/L)	ALP (IU/L)	LDH (IU/L)	Total Cholesterol (mg/L)
A	56 ± 7 ^b	114 ± 9	243 ± 51	1233 ± 134	48 ± 3
B	132 ± 73 [#]	221 ± 120 [#]	336 ± 128	1508 ± 589	54 ± 17
C	59 ± 8*	121 ± 12*	275 ± 49	1242 ± 323	49 ± 5
D	114 ± 68 [#]	252 ± 151 [#]	330 ± 77	11485 ± 395	56 ± 19
E	56 ± 9*	128 ± 15*	241 ± 60	1347 ± 414	47 ± 11

[#]*P* < 0.05 as compared with control group, **P* < 0.05, as compared with CCl₄-treated group. ^{a, b}Grouping and data presentation are as in the footnote to Table 2.

thus, no significant changes in the weights of the kidney and spleen were observed between the groups.

Histological Exam of Rat Livers

A histopathological examination was performed to monitor the morphological changes and fibrosis in the rat liver. Representative photographs of the liver morphology are shown in Fig. 2. Compared with the rat liver morphology and the state of fibrosis of the control group (Fig. 2A), CCl₄-induced liver morphological changes were evidenced by marked necrosis with fatty deposit development. Treatment with OGE or OGPE on CCl₄-intoxicated rats significantly ameliorated the CCl₄-induced steatosis and mitigated other pathological changes such as fibrosis and inflammation (Fig. 2, B, C and E). According to the products of the Masson and H&E staining, the liver morphological changes and fibrosis produced by the CCl₄ treatment were quantified as follows: 50% of CCl₄-exposed rats had liver morphological change of grade 2 severity and 100% had liver fibrosis of grade 2 or above (Table 2). OGE or OGPE exposure greatly reduced liver morphological changes and fibrosis (Table 3). The average severity scores for morphological changes and liver fibrosis in OGE- or OGPE-treated rats were significantly reduced compared with CCl₄ controls (Table 3).

Blood Serum Chemistry

The ALT value increased in the CCl₄-treated group (132 IU/l) compared with the control group (56 IU/l), and a significant difference was observed between the experimental groups (Table 4). The groups co-treated with OGE or OGPE maintained their ALT levels. These results were similar for AST values (*P* < 0.05). ALP, LDH and total cholesterol between the groups were not significantly different. The experimental results showed that co-treatment with OGE and OGPE extracts effectively inhibited liver inflammation.

Liver Lipid Peroxidation Level and Antioxidant Enzyme Activity

TBARS assay indicated a significantly increased malondialdehyde (MDA) level in the liver of rats treated with CCl₄ (15.14 nmol/mg) compared with the control group (7.98 nmol/mg) (*P* < 0.01), and the rest of the groups maintained similar MDA levels to the control group (Fig. 3, upper panel). Catalase levels decreased significantly in the CCl₄-treated group (3.24 IU/mg) compared with the control group (6.72 IU/mg) (*P* < 0.01), and the OGE- or OGPE-treated groups maintained their catalase level similar to the control group (Fig. 3, lower panel).

α-SMA Level

α-SMA is an indicator of liver fibrosis and was detected by using Western blot in this study. The results

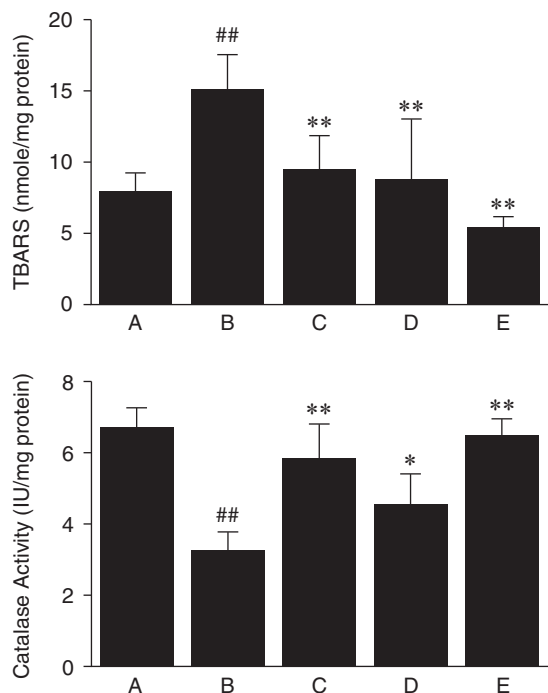


Fig. 3. Effects of OGPE on liver lipid peroxidation (upper panel) and catalase activity (down panel) after CCl₄ treatment in rats after 8 weeks. A to E are as described in the legend to Fig. 2. ^{##} $P < 0.01$ as compared with control group. ^{*} $P < 0.05$; ^{**} $P < 0.01$ as compared with CCl₄-treated group.

showed increased α -SMA levels of all groups treated with CCl₄. Treatment with OGE and OGPE reduced α -SMA increases (Fig. 4) in contrast to the level of the control group. Significant differences existed between the CCl₄-treated group and the group treated with 6 mg/kg OGPE ($P < 0.05$), and the other two *O. gratissimum*-treated groups ($P < 0.01$).

Discussion

To investigate the mechanism of the protective effects of OGE in the liver, the present study carried out a purification process, which increased the polyphenol concentration three-fold from 11.07% to 33.24%. This result allowed us to set the comparison OGPE dosage to a third that of OGE while maintaining the polyphenol content. After a short-term test, the two dosages yielded almost identical effectiveness (data not shown). OGPE also decreased CCl₄-induced liver fibrosis, lowered liver α -SMA deposition, and restored liver lipid peroxidation, liver catalase activity, and serum ALT and AST levels as effectively as regular OGE. These results suggest that polyphenols may be the primary ingredients in the treatment against liver fibrosis.

Polyphenols are free radical scavengers and me-

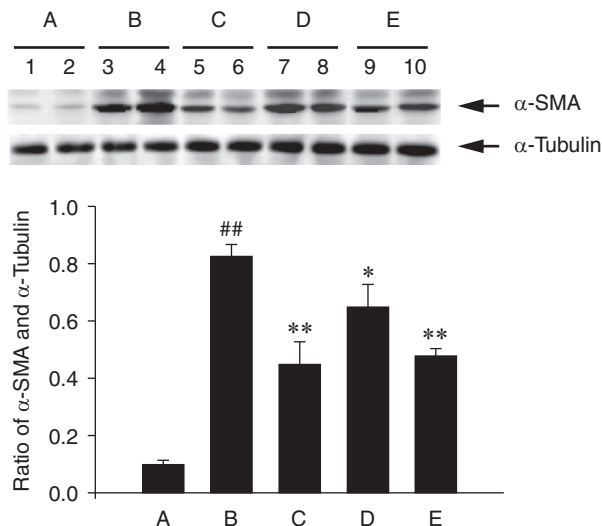


Fig. 4. Effect of OGPE on liver fibrosis marker, α -smooth muscle actin (α -SMA), after CCl₄ treatment in rats after 8 weeks. A to E are as described in the legend to Fig. 2. ^{##} $P < 0.01$ as compared with control group. ^{*} $P < 0.05$; ^{**} $P < 0.01$ as compared with CCl₄-treated group

diators of peroxidation in the body. Thus, phenolic constituents contribute to the reduction of free radicals produced by virus or chemical-induced inflammation, which can cause liver damage and fibrosis (1, 12, 29). The present data showed that various polyphenols and flavonoids were present in OGPE, including catechin, epigallocatechin gallate (EGCG) and caffeic acid. Yasuda *et al.* (37) reported that EGCG, present in 0.1% in drinking water, can partially exert an anti-fibrotic effect on the liver by targeting PDGFR β and IGF-1R. EGCG is also capable of inhibiting activation of HSC cells, which lowers liver fibril-forming collagen excretion leading to fibrosis (26). Moreover, caffeic acid phenethyl ester (2.84 mg/kg BW) attenuates BDL-induced cholestatic liver injury, bile duct proliferation and fibrosis (35), and caffeic acid also suppresses CCl₄-induced lipid peroxidation and alleviates liver damage (18). The OGPE (12 mg/kg BW) used in our experiment contained comparatively less of the individual components described in the previously mentioned research, but with catechin, caffeic acid, EGCG and rutin at less than 5%, generating a comparative result in fibrosis prevention. Notably, OGPE may contain other polyphenols from the extraction process that contributed to the increased effectiveness on liver fibrosis. Future research is required to further identify other components in the mixture.

This research demonstrated that polyphenols are the primary components responsible for scavenging free radicals and reducing oxidative stress by restoring catalase activity. In addition, OGPE, as an antioxidant source, warrants further research to be developed

as a viable option in the treatment of liver fibrosis because the polyphenols identified may only constitute a percentage of the total polyphenol content.

Acknowledgments

This work was supported by grants from the Taichung Veterans General Hospital and Tunghai University (TCVGH-T977804), and from the Chung Shan Medical University, Taiwan (CSMU 96-OM-B-040 and CSMU 93-OM-B-013), Taichung, Taiwan, Republic of China. This work was also supported by grants from the National Science Council, Republic of China (NSC102-2911-I-002-303 and NSC101-2911-I-002-303).

References

- Afanas'ev, I.B., Ostrachovich, E.A. and Korkina, L.G. Effect of rutin and its copper complex on superoxide formation and lipid peroxidation in rat liver microsomes. *FEBS Lett.* 425: 256-258, 1998.
- Aguiyi, J.C., Obi, C.I., Gang, S.S. and Igweh, A.C. Hypoglycaemic activity of *Ocimum gratissimum* in rats. *Fitoterapia* 71: 444-446, 2000.
- Atal, C.K., Sharma, M.L., Kaul, A. and Khajuria, A. Immunomodulating agents of plant origin. I: preliminary screening. *J. Ethnopharmacol.* 18: 133-141, 1986.
- Ayisi, N.K. and Nyadedzor, C. Comparative *in vitro* effects of AZT and extracts of *Ocimum gratissimum*, *Ficus polita*, *Clausena anisata*, *Alchornea cordifolia*, and *Elaeophorbium drupifera* against HIV-1 and HIV-2 infections. *Antiviral Res.* 58: 25-33, 2003.
- Aziba, P.I., Bass, D. and Elegbe, Y. Pharmacological investigation of *Ocimum gratissimum* in rodents. *Phytother. Res.* 13: 427-429, 1999.
- Bergmeyer, H.U., Horder, M. and Rej, R. International Federation of Clinical Chemistry (IFCC) Scientific Committee, Analytical Section: approved recommendation (1985) on IFCC methods for the measurement of catalytic concentration of enzymes. Part 2. IFCC method for aspartate aminotransferase (L-aspartate: 2-oxoglutarate aminotransferase, EC 2.6.1.1). *J. Clin. Chem. Clin. Biochem.* 24: 497-510, 1986a.
- Bergmeyer, H.U., Horder, M. and Rej, R. International Federation of Clinical Chemistry (IFCC) Scientific Committee, Analytical Section: approved recommendation (1985) on IFCC methods for the measurement of catalytic concentration of enzymes. Part 3. IFCC method for alanine aminotransferase (L-alanine: 2-oxoglutarate aminotransferase, EC 2.6.1.2). *J. Clin. Chem. Clin. Biochem.* 24: 481-495, 1986b.
- Chang, H.C., Chiu, Y.W., Lin, Y.M., Chen, R.J., Lin, J.A., Tsai, F.J., Tsai, C.H., Kuo, Y.C., Liu, J.Y. and Huang, C.Y. Herbal supplement attenuation of cardiac fibrosis in rats with CCl₄-induced liver cirrhosis. *Chinese J. Physiol.* 57: 41-47, 2014.
- Chaturvedi, R., George, S. and John, A. Preventive and protective effects of wild basil in ethanol-induced liver toxicity in rats. *Brit. J. Biomed. Sci.* 64: 10-12, 2007.
- Chiu, Y.W., Chao, P.Y., Tsai, C.C., Chiou, H.L., Liu, Y.C., Hung, C.C., Shih, H.C., Lai, T.J. and Liu, J.Y. *Ocimum gratissimum* aqueous extract is effective in prevention against liver fibrosis *in vivo* and *in vitro*. *Am. J. Chin. Med.* 2014. In press.
- Fraga, C.G. and Tappel, A.L. Damage to DNA concurrent with lipid peroxidation in rat liver slices. *Biochem. J.* 252: 893-896, 1988.
- Funabiki, R., Takeshita, K., Miura, Y., Shibasato, M. and Nagasawa, T. Dietary supplement of G-rutin reduces oxidative damage in the rodent model. *J. Agric. Food Chem.* 47: 1078-1082, 1999.
- George, S. and Chaturvedi, P. A comparative study of the antioxidant properties of two different species of *Ocimum* of southern Africa on alcohol-induced oxidative stress. *J. Med. Food* 12: 1154-1158, 2009.
- Hernandez-Munoz, R., Diaz-Munoz, M., Suarez-Cuenca, J.A., Trejo-Solis, C., Lopez, V., Sanchez-Sevilla, L., Yanez, L. and De Sanchez, V.C. Adenosine reverses a preestablished CCl₄-induced micronodular cirrhosis through enhancing collagenolytic activity and stimulating hepatocyte cell proliferation in rats. *Hepatology* 34: 677-687, 2001.
- Ilori, M., Sheteolu, A.O., Omonigbehin, E.A. and Adeneye, A.A. Antidiarrhoeal activities of *Ocimum gratissimum* (Lamiaceae). *J. Diarrhoeal Dis. Res.* 14: 283-285, 1996.
- Kershenobich Stalnikowitz, D. and Weissbrod, A.B. Liver fibrosis and inflammation. A review. *Ann. Hepatol.* 2: 159-163, 2003.
- Kumaravelu, P., Dakshinamoorthy, D.P., Subramaniam, S., Devaraj, H. and Devaraj, N.S. Effect of eugenol on drug-metabolizing enzymes of carbon tetrachloride-intoxicated rat liver. *Biochem. Pharmacol.* 49: 1703-1707, 1995.
- Kus, I., Colakoglu, N., Pekmez, H., Seckin, D., Ogeturk, M. and Sarsilmaz, M. Protective effects of caffeic acid phenethyl ester (CAPE) on carbon tetrachloride-induced hepatotoxicity in rats. *Acta Histochem.* 106: 289-297, 2004.
- Laemmli, U.K. Cleavage of structural proteins during the assembly of the head of bacteriophage T4. *Nature* 227: 680-685, 1970.
- Lamaison, J.L.C. and Carnet, A. Teneurs en principaux flavonoids des fleurs de *Crataegus monogyna* Jacq et de *Crataegus laevigata* (Poiret D. C) en fonction de la vegetation. *Pharm. Acta. Helv.* 65: 315-320, 1990.
- Lin, C.C., Lin, J.K. and Chang, C.H. Evaluation of hepatoprotective effects of "Chhit-Chan-Thau" from Taiwan. *Pharm. Biol.* 33: 139-143, 1995.
- Lin, C.C., Tsai, C.C. and Yen, M.H. The evaluation of hepatoprotective effects of Taiwan folk medicine 'teng-khia-u'. *J. Ethnopharmacol.* 45: 113-123, 1995.
- Llorach, R., Espin, J.C., Tomás-Barberán, F.A. and Ferreres, F. Valorization of cauliflower (*Brassica oleracea* L. var. *botrytis*) by-products as a source of antioxidant phenolics. *J. Agric. Food Chem.* 51: 2181-2187, 2003.
- Muriel, P., Garciapina, T., Perez-Alvarez, V. and Mourelle, M. Silymarin protects against paracetamol-induced lipid peroxidation and liver damage. *J. Appl. Toxicol.* 12: 439-442, 1992.
- Muriel, P. and Mourelle, M. Prevention by silymarin of membrane alterations in acute CCl₄ liver damage. *J. Appl. Toxicol.* 10: 275-279, 1990.
- Nakamuta, M., Higashi, N., Kohjima, M., Fukushima, M., Ohta, S., Kotoh, K., Kobayashi, N. and Enjoji, M. Epigallocatechin-3-gallate, a polyphenol component of green tea, suppresses both collagen production and collagenase activity in hepatic stellate cells. *Int. J. Mol. Med.* 16: 677-681, 2005.
- Nangia-Makker, P., Tait, L., Shekhar, M.P., Palomino, E., Hogan, V., Piechocki, M.P., Funasaka, T. and Raz, A. Inhibition of breast tumor growth and angiogenesis by a medicinal herb: *Ocimum gratissimum*. *Int. J. Cancer* 121: 884-894, 2007.
- Onajobi, F.D. Smooth muscle contracting lipid-soluble principles in chromatographic fractions of *Ocimum gratissimum*. *J. Ethnopharmacol.* 18: 3-11, 1986.
- Paduraru, I., Saramet, A., Danila, G., Nichifor, M., Jerca, L., Iacobovici, A., Ungureanu, D. and Filip, M. Antioxidant action of a new flavonic derivative in acute carbon tetrachloride intoxication. *Eur. J. Drug Metab. Pharmacokinet.* 21: 1-6, 1996.
- Parola, M. and Robino, G. Oxidative stress-related molecules and liver fibrosis. *J. Hepatol.* 35: 297-306, 2001.
- Poli, G., Albano, E. and Dianzani, M.U. The role of lipid peroxi-

32. Recknagel, R.O., Glende, E.A., Jr., Dolak, J.A. and Waller, R.L. Mechanisms of carbon tetrachloride toxicity. *Pharmacol. Ther.* 43: 139-154, 1989.
33. Singleton, V.L. and Rossi, J.A. Jr. Colorimetry of total phenolics with phosphomolybdic-phosphotungstic acid reagents. *Am. J. Enol. Vitic.* 16: 144-158, 1965.
34. Teselkin, Y.O., Babenkova, I.V., Kolhir, V.K., Baginskaya, A.I., Tjukavkina, N.A., Kolesnik, Y.A., Selivanova, I.A. and Eichholz, A.A. Dihydroquercetin as a means of antioxidative defence in rats with tetrachloromethane hepatitis. *Phytother. Res.* 14: 160-162, 2000.
35. Tomur, A., Kanter, M., Gurel, A. and Erboga, M. The efficiency of CAPE on retardation of hepatic fibrosis in biliary obstructed rats. *J. Mol. Histol.* 42: 451-458, 2011.
36. Waddington, E.I., Croft, K.D., Sienuarine, K., Latham, B. and Puddey, I.B. Fatty acid oxidation products in human atherosclerotic plaque: an analysis of clinical and histopathological correlates. *Atherosclerosis* 167: 111-120, 2003.
37. Yasuda, Y., Shimizu, M., Sakai, H., Iwasa, J., Kubota, M., Adachi, S., Osawa, Y., Tsurumi, H., Hara, Y. and Moriwaki, H. (-)-Epigallocatechin gallate prevents carbon tetrachloride-induced rat hepatic fibrosis by inhibiting the expression of the PDGFR β and IGF-1R. *Chem. Biol. Interact.* 182: 159-164, 2009.